

ORIGINAL ARTICLE

Outcome of PRP with Radiofrequency Ablation of Genicular Nerve for Grade III Knee Osteoarthritis

Afroza Akter¹, Nasreen Bobby², Kazi Mahzabin Arin³, Md. Saidur Rahman Khan⁴, Md. Rasheduzzaman Bhuiyan⁵, Md. Mostafa Kamal⁶, AKM Akhtaruzzaman⁷

Received: 11 March 2025

Accepted: 25 June 2025

1. Assistant Professor, Department of Anaesthesia, Pain, Palliative and Intensive Care Medicine, Dhaka Medical College and Hospital, Dhaka.
2. Anaesthesiologist, Department of Anaesthesia, Pain, Palliative and Intensive Care Medicine, Dhaka Medical College and Hospital, Dhaka.
3. Assistant Professor, Department of Anaesthesia, Analgesia and Intensive Care Medicine, Bangladesh Medical University, Dhaka.
4. Assistant Professor, Department of Anaesthesia, Intensive Care and Pain Medicine, Shaheed Suhrawardy Medical College, Dhaka.
5. Junior Consultant, Department of Anaesthesia, Intensive Care and Pain Medicine, Sir Salimullah Medical College, Dhaka.
6. Assistant Professor (OSD), DGHS, MOHFW, Clinical Fellow, Bangladesh Medical University, Dhaka.
7. Professor, Department of Anaesthesia, Analgesia and Intensive Care Medicine, Bangladesh Medical University, Dhaka.

Correspondence:

Afroza Akter
Email: shimu.smc@gmail.com

Abstract

Background: Knee osteoarthritis (OA) is a common problem in middle-aged and elderly patients. There are many non-surgical treatment modalities, including physical therapy and rehabilitation, NSAIDs, intra-articular steroids, hyaluronic acid and platelet rich plasma (PRP). Radiofrequency ablation of the genicular nerve is a new and innovative treatment option for advanced knee OA that has the capacity to decrease pain, improve function, and improve quality of life. This study aimed to observe the outcome of PRP with radiofrequency ablation (RFA) of genicular nerve in advanced knee OA.

Methods: This observational study was carried out at the Dhaka Pain Management and Research Centre. Patients with grade III osteoarthritis who received PRP with radiofrequency ablation of the genicular nerve from January 2023 to December 2024 and completed 12 months of follow-up were included in this study. The primary outcome was to assess the intensity of pain by visual analog scale (VAS) before intervention, after one week, 1, 3, 6, and 12 months. The secondary outcome was to assess functional capacity using the International Knee Documentation Committee (IKDC) scale before intervention, at 1, 3, 6, and 12 months after intervention.

Results: A total of 50 patients were included in this study. The sociodemographic characteristics depicted that the mean age of the patients was 56.2±4.94 years, 36 (72%) patients were female, and the mean BMI was 25.4±2.35 kg/m². The VAS score and IKDC score before the procedure were 6.60±0.70 and 34.02±4.52, respectively. After receiving PRP and RFA of the genicular nerve, reduction of pain intensity and improvement of functional status were observed. No complications were documented during and after interventions.

Conclusion: PRP with RFA of genicular nerve reduces pain intensity and improve functional status in patients with advanced knee OA. It could be a potential non-surgical alternative for the management of advance knee OA.

Key words: Knee OA, Radio frequency ablation, Genicular nerve, Platelet-rich plasma.

DOI: <https://doi.org/10.62848/bjpain.v5i1.4650>

Introduction

Knee osteoarthritis is a common musculoskeletal disorder in Bangladeshi adults¹. Prevalence of OA increased with age and affects the hands and knees of women than men, especially after 50 years². OA

affects physical activity due to pain, which leads to fatigue and limitation of joint function. Economic burdens include increased health care utilization and impaired quality of life³.

Knee osteoarthritis (OA) is a slowly progressive, disabling joint disorder

Citation: Akter A, Bobby N, Arin KM, Rahman MS, Bhuiyan MR, Kamal MM, Akhtaruzzaman AKM. Outcome of PRP with Radiofrequency Ablation of Genicular Nerve for Grade III Knee Osteoarthritis. Bangladesh J Pain 2025; 5(1): 22-27, doi:10.62848/bjpain.v5i1.4650

that may cause damage to the hyaline cartilage and subchondral bone⁴. Total knee arthroplasty is considered the treatment of choice for end-stage knee OA and can provide excellent postoperative pain relief, remarkable deformity correction, and satisfactory functional recovery^{5,6}. However, not all patients are appropriate candidates for surgery because of age, comorbidities, or other factors.

Non-surgical treatment modalities of knee OA commonly include physical therapy and rehabilitation, nonsteroidal anti-inflammatory medications (NSAIDs), and intra-articular steroid or viscosupplement injections. Although non-steroidal anti-inflammatory medicines (NSAIDs) can be used as a first line of treatment for osteoarthritis, their long-term usage is limited because of the development of notable side effects. These side effects include dyspepsia, bleeding in the gastrointestinal tract, hypertension, worsening of congestive heart failure, and kidney damage^{7,8}.

Conservative management is commonly effective, such modalities may not be effective in a small percentage of KOA patients, and some of them develop serious adverse effects⁹. Intraarticular steroid injection is not devoid from complications, e.g. deterioration of the articular cartilage, crystal-induced synovitis, fat necrosis, tissue atrophy, hematoma, vascular necrosis, and sepsis¹⁰. Intraarticular hyaluronic acid also has some conflicting results¹¹.

Platelet-rich plasma (PRP) is an autologous biologic treatment including patients' own plasma, containing growth factors released from platelets and endogenous fibrin scaffold¹². The rationale for the use of PRP is to stimulate the natural healing cascade and tissue regeneration by a "supra physiologic" release of platelet-derived factors directly at the site of treatment¹³. The underlying principle behind the utilization of PRP is to induce the natural healing process and tissue regeneration through release of platelet-derived growth factors directly at the treatment site^{14,15}.

One of the attractive modalities is radiofrequency ablation (RFA) of the genicular nerves. It is non-invasive in nature and low complication rate make it a more advantageous technique than other

conservative treatments. The RFA creates an electromagnetic field surrounding the electrode tip that activates adjacent molecules, thus generating frictional heat¹⁶. It is currently used to improve joint function and relieve pain by destroying nerves that innervate painful tissue or by disturbing the transmission of pain signals. Radiofrequency ablation is efficacious and safe for reducing pain and improving knee function in patients with knee osteoarthritis, without increasing the risk of adverse effects¹⁷. But the effects of the combination of PRP and RFA of the genicular nerve were not evaluated much. This study aimed to assess the outcome of PRP with radiofrequency ablation (RFA) of genicular nerve in grade III knee OA.

Methods:

This was a prospective observational study carried out at the Dhaka Pain Management and Research Centre from January 2023 to December 2024. The adult patients (40-70 years) having grade III knee osteoarthritis, refractory to conservative treatment were included in this study. Patients were excluded from this study if patients had an intra-articular steroid injection within 3 months, ongoing anticoagulant treatment, or a history of knee surgery. The demographic information and clinical profile were documented. Reduction of pain using VAS and improvement of functional status using IKDC were evaluated before and after intervention.

Study Procedures

Preparation of PRP: Patients were instructed to drink plenty of water before the procedure and avoid food for 4 hours before blood collection. PRP was obtained using the Dr PRP centrifuged machine, specialised for PRP. Eighteen millilitres of the patient's blood was obtained via venepuncture and mixed with 2 ml of anticoagulant citrate dextrose formula. The 20 ml of anticoagulated blood was put into a disposable tube and centrifuged at 3500 rpm for 4 minutes. The Plasma was separated, and again, 2nd centrifugation was done at 3500 rpm for another 4 minutes. Finally, 3-4 ml of PRP was obtained from the lower 1/3rd of the disposable tube.

USG guided PRP injection: Each patient was placed in the supine position with a pillow under the popliteal

fossa to reduce discomfort. The examined area was prepared by washing with povidon iodine and then with chlorhexidine. Sterile draping was done and the 6-13 MHz linear transducer (SonoSite M-Turbo) was covered with sterile cover. The transducer was first placed positioned transverse or longitudinal plane to the knee just below the patella and moved up to identify the suprapatellar recess, the probe was turned 90 degrees into axial plane to visualize the exact location for the injection. Before the injection of the PRP, the skin will be anesthetized with 1 ml of 1% Lidocaine infiltration. Then, needle was inserted with real time visualisation and after proper placement of the needle in the suprapatellar recess, 3-4 ml of PRP was injected. Immediately after the injection, passive flexion and extension of the affected knee were performed three times, followed by 10 minutes of resting supine.

Ultrasound-Guided Genicular Nerve Radiofrequency Ablation: Patients with same position, the transducer was first placed parallel to the long bone shaft and moved up or down to identify the epicondyle of the long bone. The probe was placed middle to the junction of the shaft and the epicondyle. The genicular arteries were identified at the junctions of the epicondyle and the shafts of the femur and tibia. Genicular artery seen as a pulsatile anechoic shadow and then confirmed with colour doppler. The superior lateral (SL), superior medial (SM), and inferior medial (IM) genicular arteries travel along each genicular nerve. So the location of the needle tip was within the vicinity of each genicular artery. After identifying the genicular arteries, the skin and subcutaneous tissue were anesthetized with 1 mL of 1% lidocaine at each target point. The needle was inserted using the long-axis view of the ultrasound probe. After positioning the needle tip next to a genicular artery, a 10 cm 22-gauge radiofrequency (RF) cannula with 10 mm active tip (NeuroTherm™, Medpoint GmbH, Hamburg, Germany) was inserted. The cannula was advanced percutaneously. To reach the desired distance between the cannula tip and the desired nerve, the cannula tip was manipulated until sensory stimulation was elicited at 0.6 V, 50 Hz, meaning that the distance between the active tip and the genicular nerve was at least 0.3 cm. To avoid inadvertent motor nerve ablation, the nerve was checked for the absence of fasciculation in its corresponding area of the lower limb with a current of 2.0 V at 2 Hz. A

volume of 2 mL of lidocaine 2% was injected before the start of the RFA; after one minute, conventional RFA at 80-90°C was performed for 90 seconds and the same procedure was administered to other genicular nerves, respectively.

Patients were given oral paracetamol (1000mg) for pain within the first 24 hours during the post-PRP injection period. The patients were also instructed to limit the use of their affected knee (limit within basic household activities, no long-standing or walking, keep the knee at rest as long as possible) for 72 hours post-injection, after which normal activities could resume. They were advised to use cold compression around the knee joint for 10-15 minutes or according to their tolerability for the next 48-72 hours.

VAS and IKDC scales were used to assess for pain intensity and functional capacity, respectively¹⁸. The VAS score was measured after 1 week, at 1, 3, 6, and 12 months, and the IKDC score was measured after 1, 3, 6, and 12 months.

Statistical analysis

SPSS (Statistical Package for Social Sciences) for Windows (version 23) was used to perform statistical analysis. Quantitative and qualitative variables were expressed as mean ± standard deviation and proportion or percentages, respectively. The results were presented using tables and/or figures. A p-value of <0.05 was considered statistically significant.

Results:

A total of 50 patients were selected in this study. The mean age of the patients was 56.2±4.94 years, and the male-to-female ratio was 1:2.5. The average BMI was 25.4±2.35 kg/m². The demographic characteristics of the patients are shown in table I.

Table I: Demographic characteristics of patients (n=50)

| Characteristics | Value |
|--------------------------|------------------------------------|
| Age (years) | 56.2±4.94 |
| Gender | Male 14(28.0%) Female 36(72.0%) |
| BMI (kg/m ²) | 25.4±2.35 |

Values are expressed as Mean ±SD and absolute number, within parenthesis percentage over column total.

The mean VAS scores at pretreatment, at 1 week, 1, 3, 6, and 12 months were 6.60 ± 0.70 , 5.65 ± 0.60 , 5.40 ± 0.66 , 4.65 ± 0.67 , 3.85 ± 0.36 , and 3.15 ± 0.46 , respectively. Figure 1 demonstrates the trend of the VAS score during the study period.

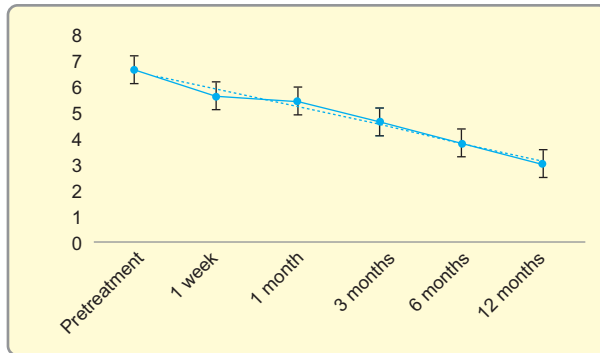


Figure 1: The trend of the VAS score during the study period.

The mean IKDC scores at pretreatment, at 1, 3, 6, and 12 months were 34.02 ± 4.52 , 37.32 ± 3.12 , 41.02 ± 2.52 , 45.40 ± 3.62 , and 55.64 ± 4.34 , respectively. Figure 2 demonstrates the trend of the IKDC score during the study period.

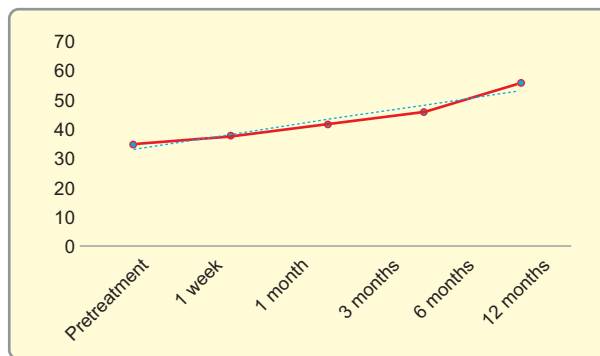


Figure 2: The trend of the IKDC score during the study period.

Discussion:

OA knee is a slowly progressive condition, the leading cause of pain and disability in most countries worldwide. This condition impairs functional capacity and decreases quality of life (QoL) by producing pain, stiffness, and limitation in the range of motion of the joint¹⁸. The choice of treatment for advanced knee OA is TKR but not all patients are appropriate candidates for surgery because of age, comorbidities,

or other factors^{5,6}. Radiofrequency ablation and PRP therapy may be an effective, non-invasive option for reducing pain and improving knee function^{15,17}. This study focused on the reduction of pain intensity and improvement of knee function after a combination of RFA of genicular nerves and PRP therapy.

In this study, the mean age of the patients was 56.2 ± 4.94 years. Females are more frequently affected than males (36 vs 14). Srikanth et al. (2005) found that knee osteoarthritis is more prevalent with increasing age and in females. Several other studies (2,3) also found increasing age as a risk factor for knee osteoarthritis.

In this study, we found that there is a reduction of pain during the study period. Elawamy et al. (2021) observed that patients who received RFA experienced sustained pain relief during whole follow-up period in comparison to those in the PRP group where pain relief was maintained for first 6 months only¹³.

Choi et al. (2011) also investigated the effectiveness and safety of fluoroscopically guided radiofrequency neurotomy in patients with KOA. Their patients who underwent radiofrequency neurotomy showed a significant decrease in VAS scale over a follow-up period of 12 months¹⁶. Kesikburun et al. (2016) reported significant pain relief and functional improvement in severe to moderate degenerative KOA after RFA procedure¹⁹.

In our study, we have performed ultrasound-guided RF ablation of genicular nerve which has been reported safer and superior to the traditional fluoroscopic guided procedure especially in the presence of anatomic variations of the genicular nerves.

On the other hand, PRP carries dual effects upon the joint's cartilage. It can stimulate the mesenchymal stem cells and fibroblasts and offer anti-inflammatory effects against the interleukin-1 β through its growth factors content such as insulin-like growth factor 1 and transforming growth factor- β ²⁰. PRP is considered as a biological therapy for tissue injury as it promotes the proliferation of synovium and cartilage derived cells²¹.

Coel et al. (2017) compared intraarticular injection of PRP versus hialuronic acid in patients with chronic

knee OA and mentioned PRP group carried better response regarding pain and disability¹⁵.

In the current study, we have found a gradual improvement in functional capacity of the patients. Several studies found the improvement of physical function after administration of PRP^{13,15,18,19,22}. Other studies observed improvement in knee function after RFA of genicular nerves^{13,16,19,23}. In our study, we have used IKDC to measure the knee function, but the above-mentioned studies used different tools like IKDC, the Western Ontario and McMaster Universities Osteoarthritis Index (WOMAC), Oxford Knee Score (OKS), and Global Perceived Effect (GPE) scale.

In our study, we found no post-procedural complications like infection, nerve injury, and allergy except post procedural pain in some patients that lasted for about 3 days. The combination of PRP and RFA reduces pain and increases knee function gradually that sustained during the whole study period.

Conclusion

PRP with radiofrequency ablation of the genicular nerve provides better pain relief and improves knee function in patients with grade III knee OA. It could be an alternative where joint arthroplasty is not a preferred option. Further randomized controlled trials are needed to evaluate the efficacy of this combined PRP and RFA of genicular nerves in advanced knee OA.

Declaration:

Author Contributions:

Conception and development of the idea: AA, AKMA

Writing: AA

Data analysis: NB, KMA, MSRK

Data collection: NB, MRB

Review and Editing: AKMA, MMK

Funding: None

Conflict of interest: None

References

1. Haider M.Z, Bhuiyan R, Ahmed S, Zahid-Al-Quadir A, Choudhury M.R, Haq S.A. and Zaman M.M. Risk factors of knee osteoarthritis in Bangladeshi adults: a national survey. *BMC Musculoskeletal Disorders*, 2022 ; 23(1), 333-342.
2. Lawrence RC, Felson DT, Helmick CG, National Arthritis Data Workgroup, et al. Estimates of the prevalence of arthritis and other rheumatic conditions in the United States Part II. *Arthritis Rheum*. 2008;58(1):23–6.
3. Helmick CG, Felson DT, Lawrence RC, et al; National Arthritis Data Work group. Estimates of the prevalence of arthritis and other rheumatic conditions in the United States. Part I. *Arthritis Rheum* 2008; 58:15-25.
4. Srikanth VK, Fryer JL, Zhai G, Win zenberg TM, Hosmer D, Jones G. A meta-analysis of sex differences prevalence, incidence and severity of osteoarthritis. *Osteoarthritis Cartilage* 2005; 13:769-781.
5. Paredes-Carnero X, Escobar J, Galdo JM, et al. Total knee arthroplasty for treatment of osteoarthritis associated with extra articular deformity. *J Clin Orthop Trauma* 2018; 9: 125–132.
6. Tani I, Nakano N, Takayama K, et al. Navigated total knee arthroplasty for osteo arthritis with extra-articular deformity. *Acta Ortop Bras* 2018; 26: 170–174.
7. Cadet C, Maheu E. Non-steroidal anti-inflammatory drugs in the pharmacological management of osteoarthritis in the very old: prescribe or proscribe? *Therapeutic Advances in Musculoskeletal Disease*. 2021;13, 1-13
8. Sostres C, Gargallo C.J. and Lanas A. Nonsteroidal anti-inflammatory drugs and upper and lower gastrointestinal mucosal damage. *Arthritis research & therapy* 2013; 15(3), 1-8.
9. Pal CP, Singh P, Chaturvedi S, Pruthi KK, Vij A. Epidemiology of knee osteoarthritis in India and related factors. *Indian J Orthop*. 2016;50:518–522.
10. Bellamy N, Campbell J, Welch V, Gee TL, Bourne R, Wells GA. Intraarticular corticosteroid for treatment of osteo arthritis of the knee. *Cochrane Data base Syst Rev* 2006; 2:CD005328
11. Korkmaz M, Erdođan Y, Okur A, Göç men AY, Günaydın Y. Comparison of the effects of intraarticular hyaluronic acid and anti-inflammatory drug treatments on the surgical intervention rates in patients with gonarthrosis. *Turk J Med Sci* 2013; 43:222-226
12. Sánchez M, Anitua E, Azofra J, Aguirre JJ, Andia I. Intra-articular injection of an autologous preparation rich in growth factors for the treatment of knee OA: a retrospective cohort study. *Clin Exp Rheumatol*. 2008;26:910–3.
13. Elawamy A, Kamel E.Z, Mahran S.A, Abdellatif H. and Hassanien M. Efficacy of genicular nerve radiofrequency ablation versus intra-articular platelet rich plasma in chronic knee osteoarthritis: A single-blind randomized clinical trial. *Pain Physician*, 2021;24(2), 127.
14. Osterman C, McCarthy MB, Cote MP, et al. Platelet-rich plasma increases anti-inflammatory markers in a human coculture model for osteoarthritis. *Am J Sports Med* 2015; 43:1474-1484.

15. Cole BJ, Karas V, Hussey K, Pilz K, Fortier LA. Hyaluronic acid versus platelet-rich plasma: A prospective, double-blind randomized controlled trial comparing clinical outcomes and effects on intra-articular biology for the treatment of knee osteoarthritis. *Am J Sports Med* 2017; 45:339-346.
16. Choi WJ, Hwang SJ, Song JG, et al. Radiofrequency treatment relieves chronic knee osteoarthritis pain: A double blind randomized controlled trial. *Pain* 2011; 152:481-487.
17. Hua Zhang, Bo Wang, Jie He and Zhongju Du. Efficacy and safety of radiofrequency ablation for treatment of knee osteoarthritis: a meta-analysis of randomized controlled trials.
18. Moinuddin M, Mony SA, Kamal MM, Islam MN, Sharmin S, Akhtaruzzaman AKM. Duloxetine in Addition with Platelet Rich Plasma in Managing Neuropathic Knee Pain: A Comparative Study. *Bangladesh J. Pain* 2022; 2(2): 18-27. doi:10.62848/bjpain.v2i2.5777
19. Kesikburun S, Ya^oar E, Uran A, et al. Ultrasound-guided genicular nerve pulsed radiofrequency treatment for painful knee osteoarthritis: A preliminary report. *Pain Physician* 2016; 19:751-759.
20. Sánchez M, Anitua E, Azofra J, Aguirre JJ, Andia I. Intra-articular injection of an autologous preparation rich in growth factors for the treatment of knee OA: a retrospective cohort study. *Clin Exp Rheumatol.* 2008;26:910–3.
21. Bai M.-Y, Vy V.P.T, Tang S.-L, et al. Current Progress of Platelet-Rich Derivatives in Cartilage and Joint Repairs. *Int. J. Mol. Sci.* 2023, 24, 1260.
22. G D, Naik D. A Study on the effects of injection of platelet rich plasma (Autologous) in the management of osteoarthritis of knee joints. *International Journal of Orthopaedics Sciences* 2020; 6(1): 1003-1010
23. Liu, J., Wang, T. & Zhu, ZH. Efficacy and safety of radiofrequency treatment for improving knee pain and function in knee osteoarthritis: a meta-analysis of randomized controlled trials. *J Orthop Surg Res* 17, 21 (2022). <https://doi.org/10.1186/s13018-021-02906-4>.